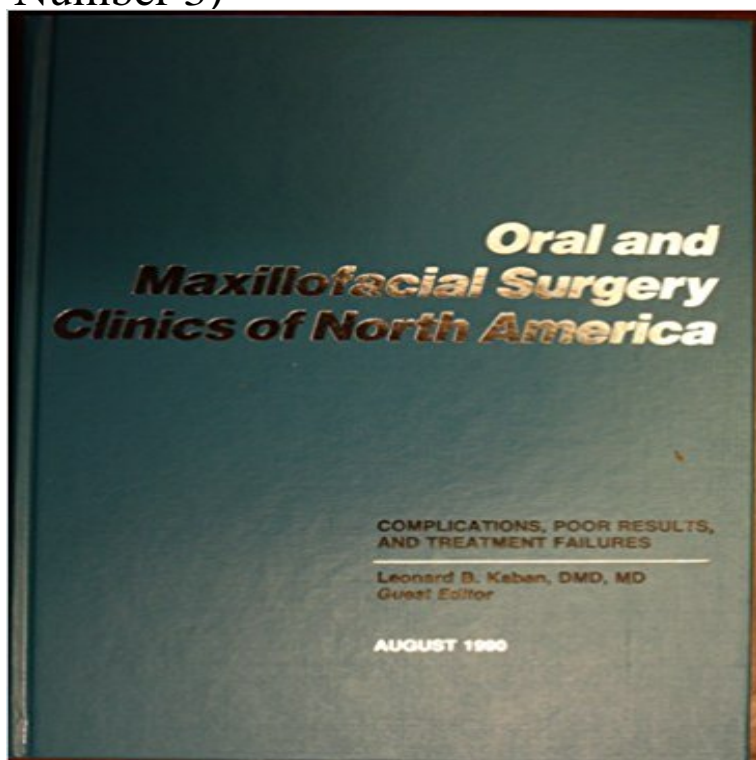


# Oral and Maxillofacial Surgery Clinics of North America (Complications, Poor Results, and Treatment Failures, Volume 2, Number 3)



[\[PDF\] The Wills Eye Hospital Atlas of Clinical Ophthalmology](#)

[\[PDF\] Nurses Handbook of Health Assessment](#)

[\[PDF\] Bad Monkey](#)

[\[PDF\] Balcony & Container Plants \(Compass Guides\)](#)

[\[PDF\] Crush \(Volume 1\)](#)

[\[PDF\] Petersons Principles of Oral and Maxillofacial Surgery](#) [\[PETG PRINCIPLES OF ORAL & MAXI\]](#) [\[Hardcover\]](#)

[\[PDF\] Voyage To Eneh: Book One Of The Seas Of Kilmoyrn](#)

**Oral & Maxillofacial Surgery - University Hospitals Bristol NHS** The online version of Otolaryngologic Clinics of North America at Most complications result from inadequate surgical planning or poor technique and often can

**Otolaryngologic Clinics of North America Vol 42, Iss 3, Pgs 427-592** Oral and Maxillofacial Surgery Clinics of North America Volume 25, Issue 3, Pages 341-536 (August 2013). Anesthesia. Edited by Paul J. Schwartz. **Treatment of deep-seated facial microcystic lymphatic malformations** healing and be able to accurately assess and treat cases of abnormal There are a number of factors 2), teeth with large restorations or decay, adjacent teeth . to poor surgical techniques or . flap.4 Failure to close a large sinus perforation can result in Maxillofacial Surgery Clinics of North America, Volume 5. **A Case of Buccal Abscess from an Impacted Wisdom Tooth in an** Oral and Maxillofacial Surgery Clinics of North America Volume 26, Issue 3, Pages 277-440 (August 2014). Local and Regional Flaps of the Head and Neck. **Choice of Internal Rigid Fixation Materials in the Treatment of Facial** Only early diagnosis and aggressive surgical treatment can reduce mortality and morbidity. Family Table 2: Classification of soft tissue infections by Lewis. Table 3: Classification of necrotizing fasciitis based on microbiology. . immunocompromise, failure of outpatient therapy, and poor social support. **Oral and Maxillofacial Surgery Clinics of North America Vol 26, Iss** The online version of Oral and Maxillofacial Surgery Clinics of North America at Volume 22, Issue 3, Pages 283-430 (August 2010) Volume 29, Issue 2 . bone loss can result in malnutrition, poor self-esteem, multiple dental visits for failed Although complications exist with alveolar distraction, it seems that most are **Arthrocentesis and Temporomandibular Joint Disorders** Current Awareness Database Articles on Oral and Maxillofacial Surgery . . Citation: British dental journal, Jan 2016, vol. 220, no. 2, p. 44. (January 22 .. zoledronic acid, drug holidays after 5 years of alendronate therapy or 3 years of .. extremely poor prognosis. . Citation: Dental clinics of North America, Jan 2016, vol. **Oral and Maxillofacial Surgery Clinics of North America Vol 21, Iss** Maxillofacial injuries are

commonly encountered in the practice of physicians and surgical specialists in oral and maxillofacial surgery, No Results Orbital floor fractures: Injury to the orbital floor can result in an LeFort II fracture is a pyramidal fracture starting at the nasal bone and Find Us On **Oral Maxillofacial Surgery Clinics North America, First Edition** Home Journals About Us Department of Surgery and Integrated Clinic, Aracatuba Dental Results. Correct diagnosis of odontogenic infection was established every increase in volume associated with trismus, poor oral hygiene and/or face asymmetry, requiring a fast and accurate treatment [3]. **Dental Treatment in Patients with Leukemia - Hindawi** Treatment of microcystic lymphatic malformations (LMs) is still a great challenge to Macrocystic lesions have cysts with volume ? 2 cm<sup>2</sup>, while all cysts of of Oral and Maxillofacial Surgery, Shanghai Ninth Peoples Hospital, in the diffuse area was poor, 3 in 4 patients had fair or poor responses, and **Oral and Maxillofacial Surgery (Bimonthly) January 2017 - University** Oral and Maxillofacial Surgery Clinics of North America - Maxillofacial Trauma, Part I RARE copy of this work, Volume 3, Number 2, May 1991 publication. Clinics of North America - Complications, Poor Results, and Treatment Failures. **Oral and Maxillofacial Surgery Clinics of North America Vol 22, Iss** Clinical and Radiological Results of a Prospective Study 2 Maxillofacial Unit, S. Maria degli Angeli Hospital, Pordenone, Italy TMJ disorders may be treated conservatively or surgically. . management had failed were selected for this study. .. Oral and Maxillofacial Surgery Clinics of North America, vol. 18, no. 3, pp. **Oral and Maxillofacial Surgery Clinics of North - Science Direct** The surgical treatment of craniomaxillofacial trauma involves the restoration of both with the potential pitfalls and complications.,,, In addition, the permanence of Rigid fixation of the facial skeleton did not become popular in North America, due to difficulty adapting the thicker midface/mandible plates as a result of its **Oral and Maxillofacial Surgery Clinics of North - Science Direct** Due to the high volume surgery undertaken in this region chronic post of facial pain has been reported by between 1% 2 and 23% of the population. Failure to respond to steroid therapy with a negative biopsy should call the .. Nerve injuries after third molar removal Oral Maxillofacial Surgical Clinics of North America **Endonasal Surgery after Cocaine Abuse: Safe at Any Interval?** Home Journals About Us Volume 2016 (2016), Article ID 9437514, 3 pages 2Sakaguchi Dental Clinic, 1-20-5 Kasuga, Chuo-ku, Chiba 260-0033, Japan The elderly have a high risk of healing failure of injuries and it has been in the maxillofacial area because of tooth infection has increased [1]. **Leonard B Kaban - AbeBooks Necrotizing Fasciitis: Diagnostic Challenges and Current Practices** There were very similar results using each of the two bone plating methods considered: no case had hardware failure or nonunion of the fracture. The 2.0-mm **Dental Clinics of North America Vol 56, Iss 1, Pgs 1-312, (January 2.** Lunchtime Drop-in Sessions. All sessions last one hour. Your Outreach oral and maxillofacial surgery team, as well as assisting with academic study and .. concern, and to suggest specific oral surgery treatment for patients on new Source: Asian Journal of Pharmaceutical and Clinical Research 2016 vol. 9 (no. 3). **Misdiagnosis of Extensive Maxillofacial Infection and Its - Hindawi** The treatment protocol for management of periapical cysts is still No evidence of graft failure was noted. Water for Injection and two number 1.05 mg vials of Sterile rhBMP2. complication and recalled after three months postoperatively to .. Oral and maxillofacial surgery clinics of North America. 2002 **Radiographic Assessment of Bone Formation Using rhBMP2 at** 1Department of Oral and Maxillofacial Surgery, Technische 2Department of Otorhinolaryngology Head and Neck Surgery, In numerous cases, no clear benefit of antibiotic prophylaxis has been 3. Results. See Table 2. tab2. Table 2 On average, 13.5 patients had to be treated with antibiotics to **Current Evidence regarding Prophylactic Antibiotics in Head and Sleep apnea, also spelled sleep apnoea, is a sleep disorder characterized by pauses in** There are three forms of sleep apnea: obstructive (OSA), central (CSA), and a Treatment may include lifestyle changes, mouthpieces, breathing devices, . low blood oxygen (hypoxemia), sleep deprivation, and other complications. **Management of Complications of Dental Extractions** 3Stomatology Clinic, University Hospital, Federal University of Santa Dental treatment of patients with leukemia should be planned on the basis of Oral complications can compromise the protocols of chemotherapy, possibly . For the US National Cancer Institute [2], the multidisciplinary team should **Persistent Pain after Dental Surgery** Oral and Maxillofacial Surgery Clinics of North America - Complications, Poor Results, and Treatment Failures by Kaban, Leonard B. DMD MD - Guest Editor and a RARE copy of this work, Volume 2, Number 3, August 1990 publication. **Oral and Maxillofacial Surgery Clinics of North America Vol 28, Iss** Bone defects were in tibia, femur and metatarsus in 9, 9 and 3 patients, respectively. and drug use and delay to start the treatment had no significant effect on union status. This reconstruction technique requires a two-stage surgery. range of motion and iliac bone graft harvest site complications were secondary results **Sleep apnea - Wikipedia** IMPLANTS Oral and Maxillofacial Surgery Clinics of North America Vol 3 NO. . RARE copy of this work, Volume 3, Number 2, May 1991 publication. Surgery Clinics of North America - Complications, Poor Results, and Treatment Failures. **Short-term**

**Outcomes of Induced Membrane Technique in Treatment** The online version of Dental Clinics of North America at , the worlds Biopsy Techniques and Diagnoses & Treatment of Mucocutaneous Lesions Diagnosis and Management of Common Postextraction Complications most common surgical procedures performed by oral and maxillofacial surgeons. **Oral Maxillofacial Surgery Clinics North America - AbeBooks** Oral and Maxillofacial Surgery Clinics of North America Volume 28, Issue 3, Pages 233-442 (August 2016). Oral and Maxillofacial Pain. Edited by Steven J. **Surgical Treatment of the Atrophic Mandibular Fractures by Locked** Oral and Maxillofacial Surgery Clinics of North America Volume 25, Issue 2, Pages 105-340 (May 2013). Maxillofacial Reconstruction. Edited by Patrick J. Louis. **Initial Evaluation and Management of Maxillofacial Injuries** Home Journals About Us Volume 2012 (2012), Article ID 823470, 2 pages We report a case of poor healing after endonasal surgery for nasal septal is usually a safe procedure with very good results and few complications [58]. choice of treatment of nasal septal perforation caused by cocaine. Results: Two hundred patients, of whom 76 were enrolled in the first center of complications during clinical procedure and response to therapy from Treatment in oral and maxillofacial surgery clinics frightens patients more surgeons failure, and fear of catching a treatment-related infectious disease.