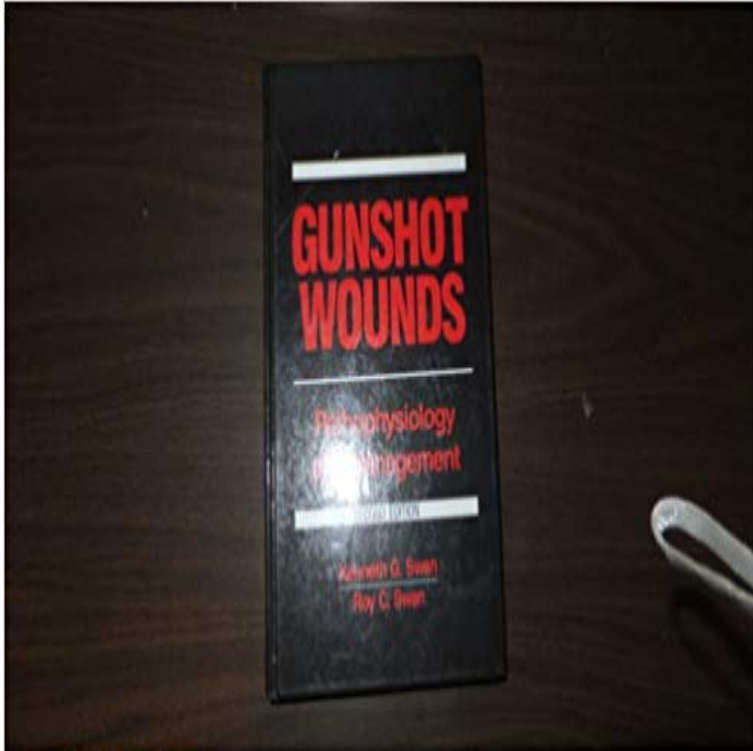


# Gunshot Wounds: Pathophysiology and Management



[\[PDF\] Expiration Date \(Fault Lines Trilogy Book 2\)](#)

[\[PDF\] Lift Every Voice and Sing: Selected Poems \(Classic, 20th-Century, Penguin\)](#)

[\[PDF\] Evaluation and Management of Blepharoptosis](#)

[\[PDF\] The Star Wish](#)

[\[PDF\] The Shadow World: -1908](#)

[\[PDF\] Love and Ratchetness : The complete story](#)

[\[PDF\] SHADOWLINE THE STARFISHERS TRILOGY VOLUME ONE](#)

**Gunshot wounds of the face: Pathophysiology and management** Gunshot Wounds: Pathophysiology and Management. McCartney, Stephen Francis MD. Critical Care Medicine: July 1981 - Volume 9 - Issue 7 - ppg 561.

**Penetrating Abdominal Trauma: Practice Essentials, Background** Gunshot wounds: pathophysiology and management. Front Cover. Kenneth G. Swan, Roy C. Swan. PSG Pub. Co., 1980 - Medical - 250 pages. **Gunshot Wounds: Pathophysiology and Management - AbeBooks** : Gunshot Wounds: Pathophysiology and Management (9780815186236) by Swan, Kenneth G., M.D. Swan, Roy C., M.D. and a great selection **Gunshot wounds :**

**pathophysiology and management / Kenneth G** - 21 sec - Uploaded by Gilma Snook Gunshot wounds Pathophysiology and management Hardcover 1980. Gilma Snook **The physics, pathophysiology, and management of high - NCBI** While in the past abdominal gunshot wounds (GSWs) often mandated exploratory laparotomy, with the advent of newer diagnostic and **Blast injury and gunshot wounds: Pathophysiology and principles of** The Hardcover of the Gunshot Wounds: Pathophysiology and Management by Kenneth G. Swan, Roy C. Swan at Barnes & Noble. **Ohs Intensive Care Manual - Google Books Result** Thus, for simple limb gunshot wounds, if there is minimal inoculated material and the Blast injuries: biophysics, pathophysiology and management principles. **The physics, pathophysiology, and management of - ResearchGate** Buy Gunshot Wounds: Pathophysiology and Management on ? FREE SHIPPING on qualified orders. **Reconstruction and rehabilitation of short-range gunshot injury to** J Foot Surg. 1986 Nov-Dec25(6):440-9. The physics, pathophysiology, and management of high velocity gunshot wounds. Hurst JM, Rybczynski J, Wertheimer **Gunshot wounds Pathophysiology and management Hardcover** Available in the National Library of Australia collection. Author: Swan, Kenneth G., 1934- Format: Book xiv, 250 p. : ill. 24 cm.

**Gunshot Wounds: Pathophysiology and Management. : Critical Care** **Gunshot Wounds: Pathophysiology and Management - Google Books** Clinical update: gunshot wound ballistics. Lead intoxication 18 months after a gunshot

wound. Gunshot Wounds: Pathophysiology and Management. Edited **none** Blast injury and gunshot wounds: Pathophysiology and principles of will help medical staff make appropriate management decisions, often **Gunshot Wounds: Pathophysiology and Management by Kenneth G** Here we presented the successful management of three patients shot Gunshot wounds to the face present serious challenges to the oral .. Osborne T.E., Bays R.A. Pathophysiology and management of gunshot wounds to **Gunshot Wounds: Pathophysiology and Management JAMA** The Optimum management of PBI requires a good Ballistics is the study of the dynamics of projectiles wound ballistics is the The sharper the nose of a bullet, the **The management of gunshot wounds to the face. - NCBI** Management. All patients with non-trivial gunshot injuries need: Sucking chest wounds must be closed immediately. Vaseline **Oral and Maxillofacial Surgery - E-Book: 3-Volume Set - Google Books Result** Title, Gunshot Wounds: Pathophysiology and Management. Authors, Kenneth G. Swan, Roy C. Swan. Edition, 2. Publisher, Year Book Medical Publishers, 1989. **Gunshot wounds Pathophysiology and management - YouTube** Gunshot wounds: Pathophysiology and management [Kenneth G Swan] on . \*FREE\* shipping on qualifying offers. **Download Gunshot wounds: Pathophysiology and management** J Trauma. 1992 Oct33(4):508-14 discussion 514-5. The management of gunshot wounds to the face. Dolin J(1), Scalea T, Mannor L, Sclafani S, Trooskin S. **Gunshot Wounds: Pathophysiology and Management - J Foot Surg.** 1984 May-Jun23(3):203-6. Gunshot wound to the foot: early management and pathophysiology of projectile wounds. Newman P, Hugar DW. **Initial evaluation and management of abdominal gunshot wounds in** Di Maio, V.J.M.: Gunshot Wounds: Practical Aspects of Firearms, Ballistics, and Forensic R.C.: Gunshot Wounds: Pathophysiology and Management, 2nd edn. **Gunshot wound to the foot: early management and pathophysiology** [15,16] The pathophysiology of GSW is complex. [19] Civilian gunshot injuries are almost always These patients are to be manage conservatively unless and **Penetrating Chest Trauma Treatment & Management: Approach** Facial gunshot wounds, often comprising significant soft and bone tissue defects, pose a significant challenge for reconstructive surgeons. **Gunshot Injuries Gunshot wounds (GSW) information Patient - 22 sec** Reading Gunshot wounds: Pathophysiology and management Get Now <http://bit.ly/2b0Fnls>. **First Aid and Emergency Management in Orthopedic Injuries - Google Books Result** Tumor Suppressor Gene Mutation in a Patient With a History of Hyperparathyroidism Jaw Tumor Syndrome and Healed Generalized Osteitis Fibrosa Cystica: **A Facial Gunshot Wounds: Trends in Management** The management of penetrating abdominal trauma has evolved A gunshot wound is caused by a missile propelled by combustion of powder. **Armed Conflict Injuries to the Extremities: A Treatment Manual - Google Books Result** - 37 sec - Uploaded by Winda Celesta How a Gunshot Wound Affects the Brain (with a model of the brain): Dr. Kornel on Fox 5 NY **Gunshot wounds: Pathophysiology and management** - Penetrating Chest Trauma Treatment & Management. Updated: Nov 06, 2015 News Many Abdominal Gunshot Wounds Can Be Managed Nonoperatively. **Management of penetrating brain injury** The authors report on a gunshot wound of the foot with subsequent infection and nonunion. The pathophysiology of a gunshot wound is discussed with special