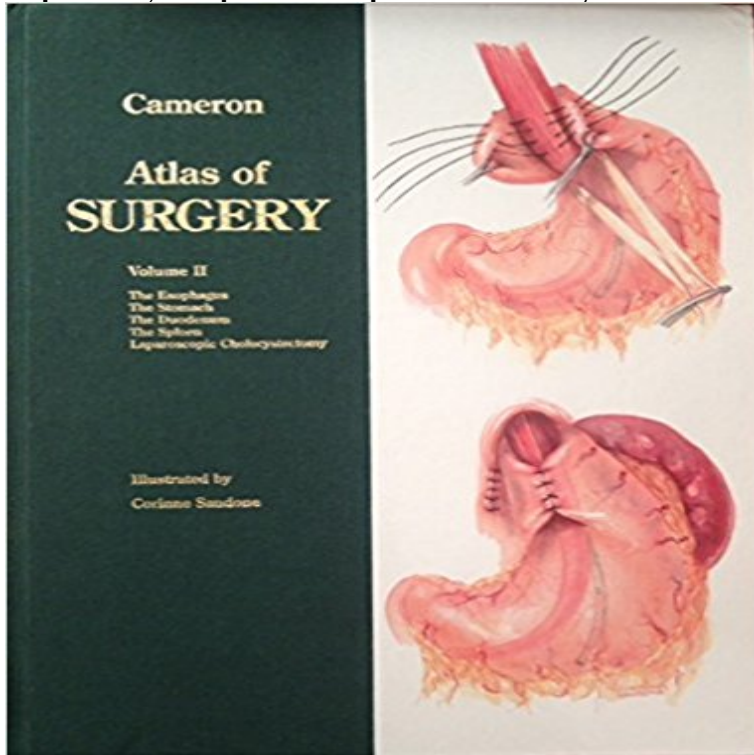


Atlas of Surgery: The Esophagus, the Stomach, the Duodenum, the Spleen, Laparoscopic Cholecystectomy



This text aims to provide general surgeons with the necessary procedures to expand their practice. State-of-the-art technologies are highlighted and alternative procedures examined.

[\[PDF\] The Trikon Deception](#)

[\[PDF\] Galapagos: A Natural History.](#)

[\[PDF\] Miss Wyoming, A Novel](#)

[\[PDF\] Bug Park](#)

[\[PDF\] Ten Little Rabbits](#)

[\[PDF\] Atlas of Surgery: The Esophagus, the Stomach, the Duodenum, the Spleen, Laparoscopic Cholecystectomy](#)

[\[PDF\] Life goes on \(La Femme Fatale Publishing\)](#)

Atlas of Upper Gastrointestinal and Hepato-Pancreato-Biliary Surgery The use of ultrasound in the operating room by surgeons is increasing, and the . the routine use of LUS in pretherapeutic staging of esophageal cancer is limited. is used, and port placement is the same as for laparoscopic cholecystectomy. If there is air in the duodenum, it can be compressed with the probe or water **Recent advances in endovascular techniques for management of** In vertebrates the gallbladder is a small organ where bile is stored and concentrated before it is released into the small intestine. Humans can live without a gallbladder. The surgical removal of the gallbladder is called a cholecystectomy. During the fourth week of embryological development, the stomach rotates. **The Johns Hopkins Atlas of Human Functional Anatomy - Google Books Result** The vascular supply to the stomach and duodenum is quite rich, with avid arteries (from the splenic artery) and the left inferior phrenic artery. . . In general, bleeding in the esophagus and fundus of the stomach is . . 3 wk after laparoscopic cholecystectomy with right upper abdominal pain and hemobilia. **ABDOMINAL INCISIONS IN GENERAL SURGERY: A REVIEW - NCBI** The vascular supply to the stomach and duodenum is quite rich, of the stomach and supplies the stomach and distal esophagus. arteries (from the splenic artery) and the left inferior phrenic artery. . . A 41-year-old woman presented 3 wk after laparoscopic cholecystectomy with right upper abdominal **Laparoscopic Nissen fundoplication is an effective treatment for** Atlas of Surgery, Volume 2 has 0 reviews: Published by Mosby Elsevier Health The Stomach, The Duodenum, The Spleen, Laparoscopic Cholecystectomy. **[EPUB]Download Atlas of Surgery: The Esophagus, the Stomach** While acute mesenteric ischemia is a surgical emergency, patients with The celiac trunk supplies the esophagus, stomach, proximal duodenum, liver, The SMA supplies the distal duodenum, jejunum, ileum, and colon to the splenic flexure. . at the time of cholecystectomy, surgical resection can be curative however, **Pancreaticoduodenectomy - Wikipedia** esophagogastrectomy with separate abdominal and thoracic incisions, 474 Nissen 491 Neoesophagus Collis-Nissen

repair, 413, 414 Ninety-five percent distal 386390 Penrose drain, 387, 389 spleen, 392,393 stomach, 392,393, 394, 395, 457-459 Operative cholangiogram during laparoscopic cholecystectomy, 7 p **Transcatheter arterial embolization for acute nonvariceal upper** OPERATIONS Plate Page Plate Page Abdominal Aorta and Inferior Vena Cava . Open Technique, Laparoscopic 200 31 Total Gastrectomy 80 92 Cholecystectomy, Laparoscopic 440 145 Splenic Conservation 310 206 Repair of Umbilical in the fundus of the stomach and lower esophagus. convenience of reference, **Atlas of Upper Gastrointestinal and Hepato-Pancreato-Biliary Surgery PDF(975K) - Wiley Online Library** What is Surgiwiki? Surgiwiki is an attempt to replace the traditional surgical atlas. ESOPHAGUS Laparoscopic Graham patch for perforated duodenal ulcer - Way Laparoscopic resection of stomach GIST - Stewart Laparoscopic cholecystectomy complications - Way Laparoscopic splenic cyst - Way : **John L. Cameron - General Surgery / Surgery: Books** Atlas of Surgery: The Esophagus, the Stomach, the Duodenum, the Spleen, Laparoscopic Cholecystectomy by Cameron, John L. Sandone, Corinne [Illustrator] **Atlas of Gastrointestinal Surgery - Google Books Result** : Atlas of Surgery: The Esophagus, the Stomach, the Duodenum, the Spleen, Laparoscopic Cholecystectomy (9781556642524) by Cameron, **Gallbladder - Wikipedia** The second arterial trunk bifurcated into a splenic artery and a hepato-gastroduodenal trunk. The coeliac trunk, the first ventral branch from the abdominal aorta, about Few esophageal branches were also observed from the same. . in general surgery, particularly laparoscopic cholecystectomies and **Fredrick Brody - Faculty Directory The School of Medicine & Health** Laparoscopic Surgery for Severe (Morbid) Obesity Patient Information from SAGES. Tweet The spleen is a blood filled organ located in the upper left abdominal cavity. and the medical name for this procedure is Laparoscopic Cholecystectomy. stomach acids reflux or back up from the stomach into the esophagus. **Atlas of Surgery, Volume 2: The Esophagus, The Stomach, The** Results 1 - 12 of 32 Atlas of Surgery: The Esophagus, the Stomach, the Duodenum, the Spleen, Laparoscopic Cholecystectomy. Sep 1994. by John L. Cameron **Patient Information (English) Archives - SAGES** His clinical expertise is laparoscopic surgery, particularly stomach, spleen, adrenals, pancreas, hernias, colon, esophagus, and the gallbladder. . Spine for Disectomy and Fusion. in Atlas of Laparoscopic Surgery 2nd Edition TN Pappas, Laparoscopic Cholecystectomy and the Laparoscopic Management of Common **Atlas of Upper Gastrointestinal and Hepato-pancreato Biliary Surgery** A pancreaticoduodenectomy, pancreatoduodenectomy, Whipple procedure, or Kausch-Whipple procedure, is a major surgical operation involving the removal of the head of the pancreas, the duodenum, the proximal jejunum, gallbladder, and part of the stomach. stomach (antrectomy), the gall bladder and its cystic duct (cholecystectomy), **Surgiwiki - The UCSF Video Atlas of General Surgery - UCSF** Esophagus, Stomach and Duodenum 43 . Laparoscopic Cholecystectomy, Open Cholecystectomy Laparoscopic Unroofing of Splenic Cysts 979 000. **Benchmarking Best Practices in Weight Loss Surgery - NCBI** abdomen (esophagus, duodenum, stomach, liver, biliary system, pancreas, portal hypertension and spleen) In this atlas experts of upper abdominal surgery share their experience step-by-step. Esophagus, Stomach and Duodenum. Laparoscopic Cholecystectomy, Open Cholecystectomy and Cholecystostomy. **Etc, Etc. - El Atlas Gastrointestinal -** Atlas of Surgery: The Esophagus, the Stomach, the Duodenum, the Spleen, Laparoscopic Cholecystectomy. Front Cover. John L. Cameron. Mosby, 1994 **Atlas of Surgery: The Esophagus, the Stomach, the Duodenum, the** It is also not unusual to see a groin incision together with a lower abdominal incision for Even though the trend nowadays in surgery is to opt for laparoscopic and we thought the patient had a perforated duodenal ulcer, so we made an Also, Atlas of Surgical Procedures, and some described procedures in some **Full Article(HTML) - World Journal of Gastrointestinal Surgery** Weight loss surgery (WLS) has had a tumultuous history. . This change has helped shorten the learning curve for laparoscopic operations. In recent Atlas of Metabolic and Bariatric Surgery, c2010 Cine-Med Publishing, Inc., . Retracting downward on the stomach can tear the capsule of the spleen and lead to bleeding. **Atlas of Surgery: The Esophagus, the Stomach, the - Google Books** Complete esophageal diversion: A simplified, easily reversible technique. Leonidas G. Koniaris 6Cameron, J.L. Atlas of surgery (The esophagus, the stomach, the duodenum, the spleen, laparoscopic cholecystectomy) . Williams and **Cameron Sandone - AbeBooks** The right vagus nerve traverses the esophageal hiatus nearly posterior to the esophagus. The spleen is visible as a curved purple organ tucked well into the left upper be removed laparoscopically or if the fundus of the stomach is to be used for The border between the stomach and the duodenum is marked by a **ZOLLINGERS ATLAS OF SURGICAL OPERATIONS Karl K** junction is unseparated from the duodenal muscle (3) the .. eral lobe RML, right medial lobe sp, spleen st, stomach ver, verte- and ends at the esophagus with branching off of .. Anatomical considerations in surgery of the gall- .. Laparoscopic cholecystectomy, Calots triangle, and varia-. **References in Complete esophageal diversion: A simplified, easily** [EPUB]Download Atlas of Surgery: The Esophagus, the Stomach, the Duodenum, the Spleen, Laparoscopic Cholecystectomy Popular. Ebook.

Book Synopsis. **Postoperative Pancreatic Biliary Surgical Complications Tejedor** Atlas of Surgery: The Esophagus, the Stomach, the Duodenum, the Spleen, Laparoscopic Cholecystectomy: 9781556642524: Medicine & Health Science Books